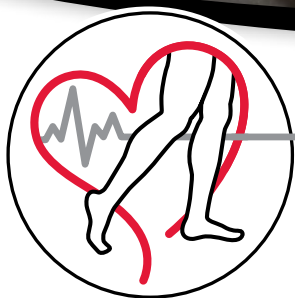

INCIRCULATION

SPRING 2015

The Official Publication for Center For Vascular Medicine™

VOLUME 1 | ISSUE 2



CENTER FOR
**Vascular
Medicine**™

CENTER FOR
Pelvic Pain
of Vascular Origin



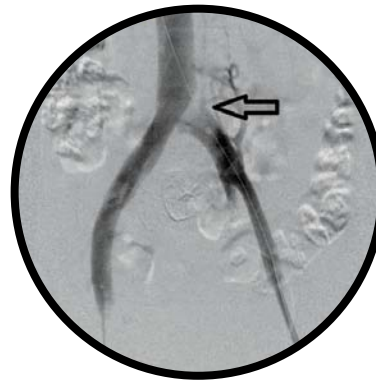A Division of the Center for Vascular Medicine

NEW HOPE FOR PELVIC PAIN

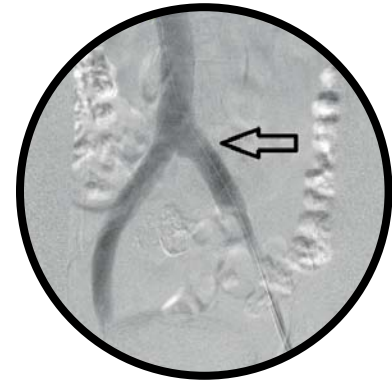
Greenbelt, MD – Lanham, Maryland resident Charmaine Martinez had suffered with pain in her pelvis for more than two years and saw multiple physicians before getting two correct diagnoses: Pelvic Congestion Syndrome and May Thurner Syndrome. Fortunately, she found two experienced vascular specialists, Dr. Sanjiv Lakhanpal and Dr. Vinay Satwah, at the Center for Pelvic Pain of Vascular Origin, a division of the Center for Vascular Medicine (CVM), to diagnose and treat the cause of her pain.

Center for Vascular Medicine has been recognized as a national leader in the treatment of deep venous conditions, including disorders in the pelvic region. They are among a small group of facilities that can treat these conditions on an outpatient basis. Dr. Vinay Satwah, an international expert in the field, was invited to speak at a vascular conference on this topic in 2014.

The 42-year-old Martinez, who has five children and two grandchildren, has lots of company. Up to 15% of women aged 20 to 50 have Pelvic Congestion Syndrome, which is characterized by insufficient flow in the veins of their pelvis, somewhat like having varicose leg veins. As many as 60% of those women have pain that can be debilitating. Having multiple children can increase the risk of this condition. The problem can be difficult to diagnose, as lying down during the pelvic exam often relieves the congestion.



BEFORE



AFTER

Martinez initially was treated for numerous varicose veins in her legs. A few years later, however, she began experiencing pain in her pelvic area. The pain got so intense that she quit her job as a phlebotomist and she had to move from the third floor to the first floor because she could not climb stairs.

After performing a thorough history and physical plus a highly specialized pelvic ultrasound, the doctors at CVM discovered an enlarged, compressed pelvic vein on her left side. They subsequently performed a venogram to pinpoint that the problem was located in the left ovarian vein. Minimally invasive treatment (involving an injection of medicine) that closed off the problematic vein relieved the pain for months.

The doctors found that a second vein, the common iliac vein, was also severely compressed and would need surgical treatment. "It was excruciating," Marti-

nez recalls. "I was crying every day."

However, her insurance refused to pay for the venous procedure Martinez needed to fix the second vein. In this procedure, doctors insert a tiny balloon into the affected vein to open it up, then insert a metallic stent to keep it open. Martinez recalls, "While treating my leg veins, Dr. Lakhanpal asked how I was. I broke down and sobbed. I told him I couldn't get out of bed and had to walk hunched over. He was so caring and considerate. He said he would take care of me. He reduced his fee and scheduled me for a stent procedure in September of 2014."

After a brief recovery period, Martinez describes how having these two procedures has changed her life. "It was like my whole entire life was back again. I couldn't believe that I could clean in hard to reach places, bend over, and do all of the activities I normally did again. I'm so happy. It was a miracle."

CVM TO BEGIN DIALYSIS ACCESS PROGRAM

Center for Vascular Medicine is excited to announce that it will be providing dialysis access vascular services. The program will be led by Michael Malone, MD, FACS, who has extensive experience in this area of vascular medicine. Dr. Malone is a board certified vascular surgeon who has been providing this specialty service for over 17 years. He has worked in various hospitals in Ohio and New Jersey providing valuable and essential care to thousands of patients with end stage renal disease. As the dialysis patient population continues to grow, Center for Vascular Medicine will be on the forefront to meet demands, as a leader in outpatient based vascular care.

OUTPATIENT SERVICES PROVIDED:

- Vein Mapping
- Placement of A-V Grafts and Fistulas
- Assessment of Malfunctioning Access Site
- Temporary Dialysis Catheter Placement
- Declotting of Occluded Access Site
- Fistula Maturation
- Percutaneous Endovascular Revisions
- Routine Monitoring at the Discretion of the Referring Physician

CVM RECEIVES VASCULAR TESTING ACCREDITATION BY THE IAC



Cardiovascular diseases are the No. 1 cause of death in the United States. On average, one American dies every 39 seconds of cardiovascular disease – disorders of the heart and blood vessels. Stroke, a disorder of the blood supply to the brain, is the third leading cause of death and the leading cause of disability in the country, with nearly 800,000 new strokes occurring annually. According to the American Heart Association, the total direct and indirect cost of cardiovascular disease and stroke in the U.S. for 2010 was an estimated \$503.2 billion.

Early detection of life-threatening heart disorders, stroke and other diseases is possible through the use of vascular testing procedures performed within hospitals, outpatient centers and physicians' offices. While these tests are helpful, there are many facets that contribute to an accurate diagnosis based on vascular testing. The skill of the technologist performing the examination, the type of equipment used, the background and knowledge of the interpreting physician and quality assurance measures are each critical to quality patient testing.

Center for Vascular Medicine has been granted a three-year term of accreditation in vascular testing in the areas of Peripheral Arterial Testing by the Intersocietal Accreditation Commission (IAC).

Accreditation by the IAC means that Center for Vascular Medicine has undergone a thorough review of its operational and technical components by a panel of experts. The IAC grants accreditation only to those facilities that are found to be providing quality patient care, in compliance with national standards through a comprehensive application process including detailed case study review.

IAC accreditation is a "seal of approval" that patients can rely on as an indication that the facility has been carefully critiqued on all aspects of its operations considered relevant by medical experts in the field of vascular testing. When scheduled for a vascular testing procedure, patients are encouraged to inquire as to the accreditation status of the facility where their examination will be performed and can learn more by visiting www.intersocietal.org/vascular/main/patients.htm.

IAC accreditation is widely respected within the medical community, as illustrated by the support of the national medical societies related to vascular testing, which include physicians, technologists and sonographers. Vascular testing accreditation is required in some states and regions by the Centers for Medicare and Medicaid Services (CMS) and by some private insurers. However, patients should remain vigilant in making sure that their vascular testing procedures are performed within accredited facilities, because for many it remains a voluntary process.

WELCOME DR. MICHAEL MALONE

Dr. Michael Malone joins Center for Vascular Medicine (CVM) with a special interest in complex peripheral interventions, as well as open vascular surgical procedures. Prior to joining CVM, he was clinical assistant professor of surgery at the University of Toledo School of Medicine and the University of Medicine and Dentistry of New Jersey/ Cooper Hospital. Previously, he was an attending vascular surgeon at Blanchard Valley Health System and Mercy Hospital of Tiffin for several years. Dr. Malone complements CVM with a wide breadth of significant surgical knowledge and experience from numerous academic and hospital appointments. His work has been published in several vascular surgery journals and textbooks.



WELCOME JEANNE SANDERS

Jeanne brings a varied skill set and wide base of knowledge to Center for Vascular Medicine (CVM), having over 18 years of experience in the health-care arena of business management and development. Most recently, she served as CEO of Horizon Vascular Specialists in Maryland. Prior to Horizon, Jeanne was a corporate vice president of community care for the Adventist Health Care System and senior vice president of Shady Grove Adventist Hospital. Throughout her career, Jeanne has been instrumental in business planning and development, successfully implementing growth strategies as well as being a key player in decisions involving day to day business practices. Jeanne is an integral part of the daily management of CVM in her multi-faceted role, which includes the oversight of Operations, Finance and Clinical Scheduling. She is a key player in the continued implementation of CVM's core mission of 'state of the art vascular care in a compassionate and cost efficient manner.' Jeanne has a Bachelor's Degree in Nursing from Washington Adventist University and a Master's Degree Nursing/Health Care Administration from Georgetown University.



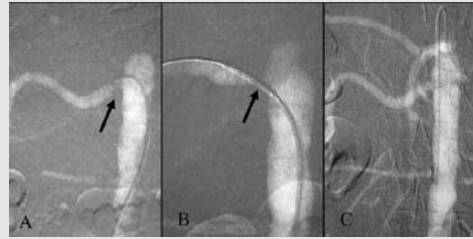
CVM INTRODUCES CO₂ ANGIOGRAPHY

Center for Vascular Medicine (CVM) is pleased to offer an additional modality to increase its efficacy in treating certain patients suffering from lifestyle-limiting Peripheral Artery Disease (PAD). After an abnormal non-invasive diagnostic work-up, the patient may need further invasive evaluation, in the form of an angiogram. This is traditionally performed with fluoroscopy and injection of contrast into the arterial system, likely in the angiography suite by an Interventional Vascular specialist.

However, there exists a subset of patients who have severe allergic reactions to iodinated contrast, in which special consideration should be made to avoid exposure. Additionally, in patients who have abnormal baseline kidney function, with elevated blood urea nitrogen (BUN) levels and/or creatinine levels, minimization of contrast administration is important. Some patients may have known Chronic Kidney Disease (CKD), but have not shown the progression of disease to the point where hemodialysis is required. It is critical to be conservative with the amount of contrast usage in these patients as they are at increased risk for contrast-induced nephropathy (CIN).

Therefore, in an effort to provide the highest quality of vascular care to all patients, Center for Vascular Medicine (CVM) has incorporated the utilization of carbon dioxide (CO₂) in performing invasive diagnostic studies and interventions. When injected into the vascular system, CO₂ gas has chemical properties that allow the visualization of vessels under fluoroscopy. This allows an alternative approach to angiography while avoiding contrast exposure. With the availability of high-resolution digital subtraction angiography (DSA) and a reliable gas delivery system, CO₂ angiography has become widely used for vascular imaging and guidance during endovascular procedures, including angioplasty and stent placement, transcatheter embolization, and endovascular abdominal aortic aneurysm (AAA) repair. Since CO₂ is a colorless and odorless gas, and it cannot be visually distinguished from air, pressurized cylinders are used to contain the gas. Unlimited amounts of CO₂ may be used for vascular imaging because the gas is effectively eliminated by means of respiration. Although very useful, the overall quality of CO₂ vascular images is slightly less than that obtained with contrast medium. Therefore, routine use is not desirable for complex interventional procedures, requiring precision in imaging quality.

It is important to note that incorrect application of technique may result in air contamination, which may cause serious complications. Therefore, a thorough understanding of the unique physical properties of CO₂ is necessary for the safe and effective performance of CO₂ angiography. The highly skilled and board-certified physicians at Center for Vascular Medicine (CVM) have received specialized training in performing CO₂ angiography.



Carbon dioxide guided stent placement of right renal artery stenosis. A. CO₂ DSA demonstrates orifice stenosis of right renal artery (arrow). B. DSA with the injection of CO₂ through the sheath demonstrates the stent in good position (arrow). C. After stent deployment, the renal artery is widely patent.



Sanjiv Lakhanpal, MD



Vinay Satwah, DO



Mike Malone, MD



Gaurav Lakhanpal, MD



Rakesh Wahi, MD



Shekeeb Sufian, MD



Tom Militano, MD



Krutiben Patel, PA-C

REFERENCES:

Moos JM, Ham SW, Han SM, et al. Safety of carbon dioxide digital subtraction angiography. *Arch Surg.* Dec 2011;146(12):1428-32.

Nadolski GJ, Stavropoulos SW. Contrast alternatives for iodinated contrast allergy and renal dysfunction: options and limitations. *J Vasc Surg.* Feb 2013;57(2):593-8.

Call today to make a referral:

866-916-9202

www.cvmus.com



IMMEDIATE APPOINTMENTS AVAILABLE

Annapolis | Glen Burnie | Greenbelt | Prince Frederick | Silver Spring